

ORIGINAL ARTICLE

Telomerase Mutations in Families with Idiopathic Pulmonary Fibrosis

Mary Y. Armanios, M.D., Julian J.-L. Chen, Ph.D., Joy D. Cogan, Ph.D., Jonathan K. Alder, B.A., Roxann G. Ingersoll, B.S., Cheryl Markin, B.S., William E. Lawson, M.D., Mingyi Xie, B.S., Irma Vulto, B.S., John A. Phillips III, M.D., Peter M. Lansdorp, M.D., Ph.D., Carol W. Greider, Ph.D., and James E. Loyd, M.D.

ABSTRACT

BACKGROUND

Idiopathic pulmonary fibrosis is progressive and often fatal; causes of familial clustering of the disease are unknown. Germ-line mutations in the genes *hTERT* and *hTR*, encoding telomerase reverse transcriptase and telomerase RNA, respectively, cause autosomal dominant dyskeratosis congenita, a rare hereditary disorder associated with premature death from aplastic anemia and pulmonary fibrosis.

METHODS

To test the hypothesis that familial idiopathic pulmonary fibrosis may be caused by short telomeres, we screened 73 probands from the Vanderbilt Familial Pulmonary Fibrosis Registry for mutations in *hTERT* and *hTR*.

RESULTS

Six probands (8%) had heterozygous mutations in *hTERT* or *hTR*; mutant telomerase resulted in short telomeres. Asymptomatic subjects with mutant telomerase also had short telomeres, suggesting that they may be at risk for the disease. We did not identify any of the classic features of dyskeratosis congenita in five of the six families.

CONCLUSIONS

Mutations in the genes encoding telomerase components can appear as familial idiopathic pulmonary fibrosis. Our findings support the idea that pathways leading to telomere shortening are involved in the pathogenesis of this disease.

From the Department of Oncology (M.Y.A., C.W.G.), the Graduate Program in Cellular and Molecular Medicine (J.K.A.), the Institute of Genetic Medicine (R.G.I.), and the Department of Molecular Biology and Genetics (C.W.G.), Johns Hopkins University School of Medicine, Baltimore; the Department of Chemistry and Biochemistry (J.J.-L.C., M.X.) and the School of Life Sciences (J.J.-L.C.), Arizona State University, Tempe; the Departments of Pediatrics (J.D.C., J.A.P.) and Medicine (C.M., W.E.L., J.E.L.), Vanderbilt University School of Medicine, Nashville; the Veterans Affairs Medical Center, Nashville (W.E.L.); and the Terry Fox Laboratory (I.V., P.M.L.) and the British Columbia Cancer Agency and the Department of Medicine (P.M.L.), University of British Columbia, Vancouver, BC, Canada. Address reprint requests to Dr. Armanios at the Department of Oncology, Johns Hopkins University School of Medicine, 1650 Orleans St., CRB 186, Baltimore, MD 21231, or at marmani1@jhmi.edu.

N Engl J Med 2007;356:1317-26.

Copyright © 2007 Massachusetts Medical Society.

IDIOPATHIC PULMONARY FIBROSIS HAS A predictable, progressive clinical course that ultimately leads to respiratory failure. Irreversible fibrosis is the hallmark of the disease, which has a characteristic radiographic appearance most often associated with the pathological lesion of usual interstitial pneumonia. Although both genetic and environmental factors have been implicated, the cause of idiopathic pulmonary fibrosis is unknown — as, indeed, its name implies. Treatment approaches that target the immune system have not proved to be successful.¹ From 2 to 20% of patients with idiopathic pulmonary fibrosis have a family history of the disease; inheritance appears to be autosomal dominant with variable penetrance.¹⁻³ Aside from one large kindred with a mutation in the gene encoding surfactant protein C in affected family members, the genetic basis of familial forms of idiopathic pulmonary fibrosis is not understood.⁴

Telomerase is a specialized polymerase that adds telomere repeats to the ends of chromosomes.⁵ It has two essential components: a catalytic component, telomerase reverse transcriptase (hTERT), and an RNA component (hTR); the latter provides the template for nucleotide addition by hTERT.⁶⁻⁸ The addition of telomeric repeats (a repeat comprising the six nucleotides — TTAGGG — complementary to the template in hTR) onto the ends of the chromosome partly offsets the shortening that occurs during DNA replication. Telomeres shorten with each cell division and ultimately activate a DNA damage response that leads to apoptosis or cell-cycle arrest.⁹⁻¹³ Telomere length thus limits the replicative capacity of tissues and has been implicated in age-related disease.^{9-11,14,15}

Dyskeratosis congenita is a rare hereditary disorder initially described on the basis of a triad of mucocutaneous manifestations: skin hyperpigmentation, oral leukoplakia, and nail dystrophy.¹⁶ The most common cause of death in patients with dyskeratosis congenita is bone marrow failure due to aplastic anemia. Pulmonary disease is present in 20% of patients and is the second most common cause of death.¹⁶⁻¹⁸ The X-linked form of dyskeratosis congenita is severe and associated with mutations in the *DKC1* gene.¹⁹ Autosomal dominant cases of dyskeratosis congenita are rare, can present later in adulthood, and often lack the classic skin manifestations. In some families, the hematopoietic defects develop first, implying that despite the originally given name, the dyskerato-

sis is not canonical.²⁰ Heterozygous mutations in *hTR* and *hTERT*, the essential components of telomerase, underlie the genetic defect in families with dominant inheritance, indicating that half the usual dose of telomerase is inadequate for telomere maintenance, and tissues of high turnover, such as the bone marrow, are susceptible.²¹⁻²⁴ In autosomal dominant dyskeratosis congenita, anticipation can be seen in which phenotypes present earlier and more severely in successive generations.^{21,24,25} This pattern implies that in these patients, it is not the telomerase mutation itself but the short telomeres that determine the severity of the disease.^{14,24,26}

We recently identified a pedigree with autosomal dominant dyskeratosis congenita that carried a null *hTERT* allele but lacked the typical mucocutaneous features.²⁴ In this kindred, pulmonary fibrosis was dominantly transmitted and was the only manifestation of disease in one mutation carrier. The clinical presentation and pattern of fibrosis in this subject were typical of the idiopathic form of the disease. Since familial idiopathic pulmonary fibrosis is also dominantly inherited, we hypothesized that telomere shortening causes this disease and that mutations in telomerase may contribute to it.

METHODS

SUBJECTS

Subjects and their families were recruited into the Vanderbilt Familial Pulmonary Fibrosis Registry on the basis of the presence of two or more cases of idiopathic pulmonary fibrosis. (We did not limit families to those in which only first-degree relatives were affected.) Subjects were excluded from the study if they had a secondary cause of pulmonary fibrosis or if they had skin manifestations suggestive of dyskeratosis congenita. Subjects were recruited from the Vanderbilt Idiopathic Pulmonary Fibrosis Clinic or were referred from other sites in North America between 1996 and 2004. The study was approved by the local institutional review boards, and written informed consent was obtained from all subjects. Diagnostic confirmation was based on a detailed clinical assessment (Table 1, and Table 1 of the Supplementary Appendix, available with the full text of this article at www.nejm.org). We used the consensus classification of idiopathic interstitial pneumonia in individual cases.²⁷ At the time the

registry was accessed, all 73 probands were reported by their clinicians to be North Americans of European descent.

SEQUENCE ANALYSIS

Genomic DNA was isolated from peripheral blood with the use of standard methods. We amplified and sequenced *hTR* in both directions, as described previously.²¹ We amplified and sequenced the 16 exons of *hTERT* and its 3' untranslated region with the use of primers listed in Table 2 of the Supplementary Appendix. Amplicons of *hTERT* were sequenced in one direction, and suspected changes were confirmed in the opposite strand. Mutations in the probands and their relatives were confirmed by bidirectional sequencing. Sequences were inspected manually with the use of Sequencher software, and variants were compared with public databases. Coding and noncoding variants are listed in Table 3 of the Supplementary Appendix.

TELOMERES AND TELOMERASE

A reverse-transcriptase-polymerase-chain-reaction (RT-PCR) assay was performed with the use of RNA isolated from peripheral blood to make complementary DNA (cDNA). Primers were designed to span exons where a mutation was predicted to alter splicing; primer sequences are available on request. PCR products were cloned, and the sequence was verified.

The average length of telomeres was measured in peripheral-blood lymphocytes by flow fluorescence in situ hybridization (FISH), as described previously.²⁸

Point mutations were generated, and the telomerase complex was reconstituted in vitro.²⁴ Telomerase activity was assayed without amplification, with the use of a modified direct assay.^{29,30}

RESULTS

MUTATIONS AFFECTING TELOMERASE COMPONENTS

Of 73 probands who were screened, 6 (8%) had heterozygous mutations in *hTERT* or *hTR*. Five probands had mutations in *hTERT* (two missense, two splice junction, and one frameshift), and one proband had a mutation in *hTR* (Table 1, and Fig. 1 of the Supplementary Appendix). None of the *hTERT* mutations were present in 623 unaffected subjects, as determined in other studies.^{23,31} Of these subjects, 140 described themselves as white, with the rest describing themselves as black,

Table 1. Mutations in Telomerase and Associated Clinical Features of the Six Probands.*

Proband No.	Mutation	Sex	Age At Onset of Study yr	Presenting Symptom	Smoking History	Pulmonary Function			Findings on Lung Biopsy		Complete Blood Count			
						TLC liters (% of predicted value)	FVC liters (% of predicted value)	DLCO	Usual	Usual	WBC per mm ³	Hgb g/dl	Platelet per mm ³	
AII.1	<i>hTERT</i> CTG→CAG Leu55Gln	M	77	81	Dyspnea	None	4.45 (68)	3.02 (68)	14.2 (76)	Usual	interstitial pneumonia	5,500	14.0	206,000
BIII.5	<i>hTERT</i> IVS1+1 G→A	M	58	67†	Cough	None	3.17 (44)	2.10 (44)	12.5 (49)	Usual	interstitial pneumonia	8,800	14.1	282,000
CII.7	<i>hTERT</i> codon 112 del C	M	58	61	Dyspnea	30 pack-years	5.28 (69)	3.55 (66)	12.8 (47)	Usual	interstitial pneumonia	8,800	16.2	201,000
DIII.2	<i>hTERT</i> IVS9-2 A→C	F	48	49†	Dyspnea	32 pack-years	NA	1.31 (43)	NA	Idiopathic	interstitial pneumonia	10,800	13.8	235,000
EII.2	<i>hTERT</i> ACG→ATG Thr1110Met	F	68	76	Dyspnea	None	3.25 (68)	1.69 (47)	12.5 (54)	Usual	interstitial pneumonia	9,500	15.5	317,000
FIII.5	<i>hTR</i> 98 G→A	F	60	66†	Dyspnea	None	2.48 (51)	1.2 (45)	7.07 (32)	Usual	interstitial pneumonia	6,800	12.8	218,000

* Identifiers for all probands refer to subjects shown in Figure 1. TLC denotes total lung capacity, FVC forced vital capacity, DLCO carbon monoxide diffusing capacity, WBC white cells, Hgb hemoglobin, IVS intervening sequence between exons (intronic), and NA not available.
† The age at the time of death is shown.

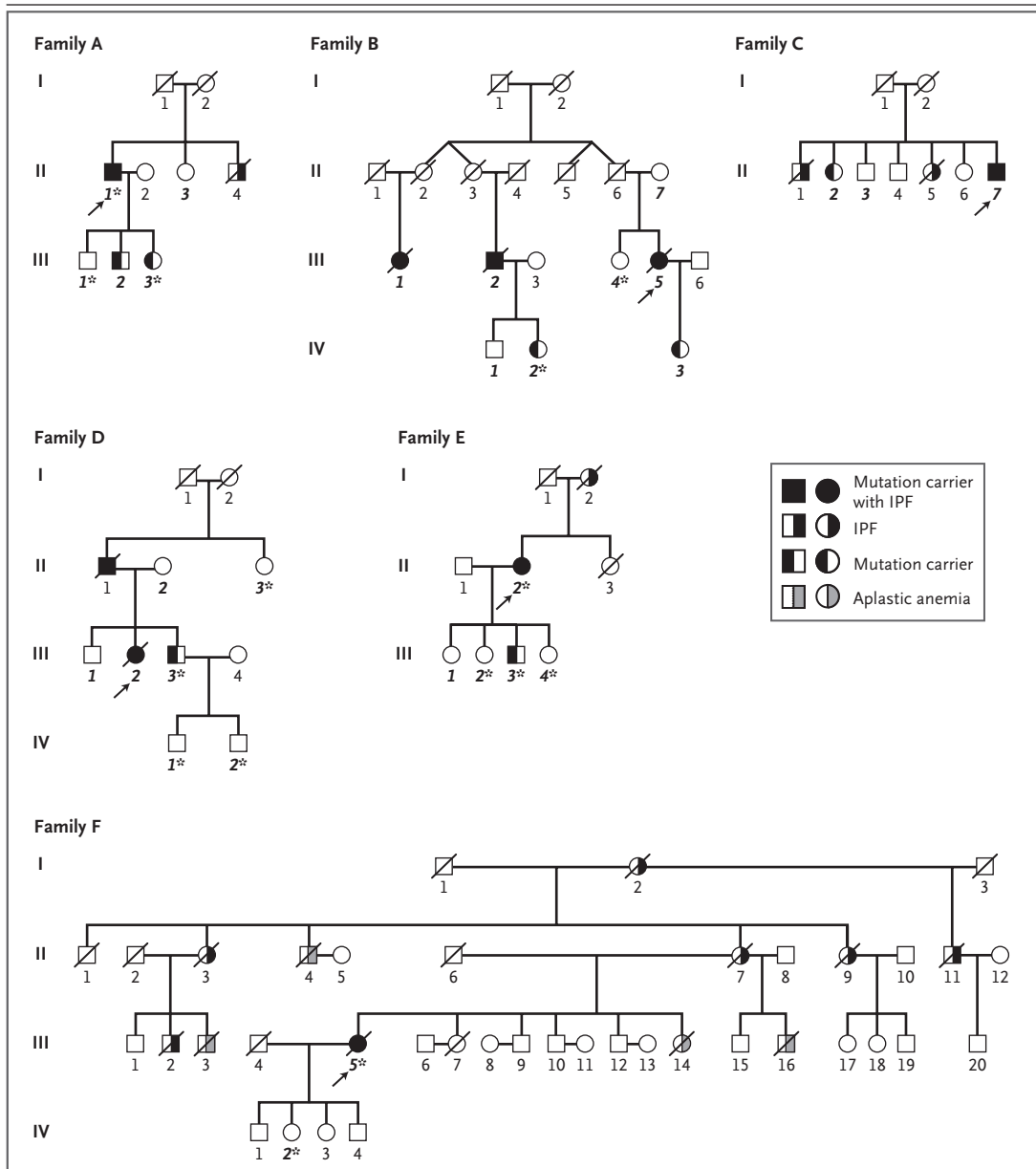


Figure 1. Pedigrees of Six Probands with Telomerase Mutations.

Arrows point to the proband in each family, and bold italic numbers indicate subjects for whom DNA was available for sequencing. Subjects in whom telomere length was measured are indicated by asterisks. Mutation status is indicated by the symbols shown in the key, with squares indicating male sex and circles indicating female sex. Deceased family members are indicated by slashes through the symbols. In Family D, Subject DII.1 is an obligate carrier, given that two of his children carry the mutation and the mother does not. A total of 19 subjects with confirmed idiopathic pulmonary fibrosis are included among the six families shown. The seven asymptomatic carriers in younger generations were on average 11 years younger than the probands at the time of diagnosis: 40, 44, 46, 50, 52, 55, and 68 years of age. In Family F, three subjects had aplastic anemia, and Subject FIII.16 died from acute myeloid leukemia, probably in the setting of aplastic anemia. IPF denotes idiopathic pulmonary fibrosis.

Hispanic, or Asian. The *hTR* mutation was also absent in 194 healthy controls. Of these subjects, 123 described themselves as white, with the remaining subjects describing themselves as black, Hispanic, or Asian.²²

MUTATIONS ASSOCIATED WITH DISEASE AND SHORT TELOMERES

To determine whether telomerase mutations segregated with idiopathic pulmonary fibrosis in families, we examined the pedigrees. The pattern of inheritance was consistent with autosomal dominant inheritance of the disease (Fig. 1). The mutant allele was present in affected subjects and was generally absent in asymptomatic subjects of the same generation. We identified mutation carriers who did not have symptoms of the disease. These subjects were on average 11 years younger than the probands at the time of diagnosis (Fig. 1). This observation is consistent with the variable penetrance associated with familial idiopathic pulmonary fibrosis and also suggests that the onset of disease may be age dependent.

To assess whether mutant telomerase is asso-

ciated with short telomeres, we measured the telomere length in lymphocytes. The average telomere length was significantly less in the probands and asymptomatic mutation carriers than in their relatives who did not carry the mutation ($P=0.006$) (Fig. 2A). A comparison of the telomere length in mutation carriers with that in 400 healthy controls, according to age,²³ showed that mutation carriers fell below the 10th percentile of the controls ($P=0.018$), whereas their relatives who were noncarriers clustered near the median ($P=0.575$) (Fig. 2B). Mutant telomerase was therefore associated with short telomeres.

IMPAIRED ACTIVITY OF MUTANT TELOMERASE

We next examined the consequences of *hTERT* and *hTR* mutations on telomerase function. We first examined the two missense mutations in *hTERT*, glutamine replacing leucine at residue 55 (Leu55Gln) and methionine replacing threonine at residue 1110 (Thr1110Met). The Leu55Gln substitution identified in the proband of Family A is in a highly conserved region of the N-terminal; an amino acid substitution of Leu55 may alter telo-

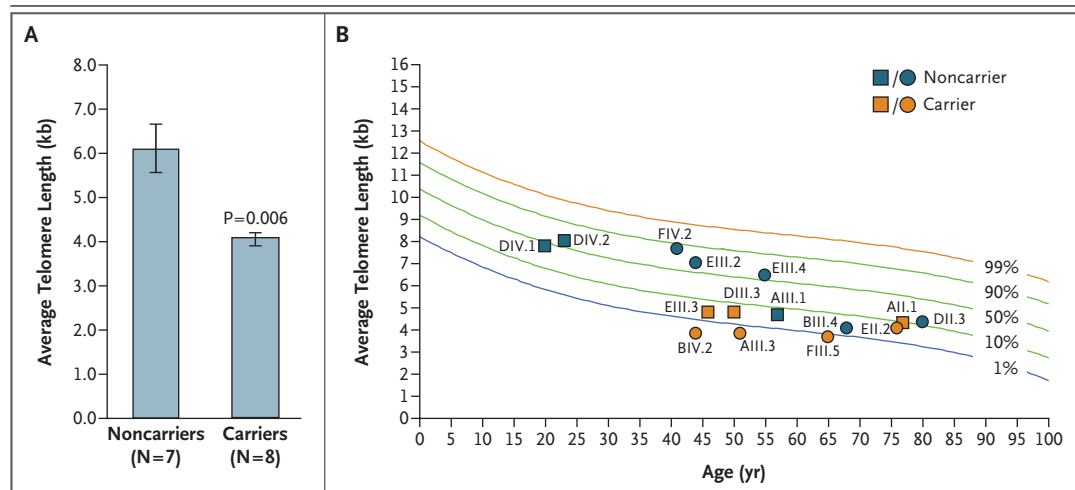


Figure 2. Telomere Length in Mutation Carriers and Their Relatives.

Panel A shows the average length of telomeres in lymphocytes in eight carriers and seven noncarriers of the genetic mutation, and Panel B shows telomere length as a function of age. The three oldest mutation carriers are the probands in Family A, Family E, and Family F. The 12 other subjects who were examined are indicated in Figure 1 by an asterisk. Identifiers refer to subjects from the pedigrees in Figure 1. I bars represent standard errors. Telomere lengths in mutation carriers were significantly less than the median value for their age ($P=0.018$ by the Wilcoxon signed-rank test), whereas telomere lengths in noncarriers did not differ significantly from the median for their age ($P=0.575$).

merase RNA binding and thus the catalytic efficiency of telomerase.³² The Thr1110 residue is also highly conserved and lies in the C-terminal of hTERT, a domain that is thought to mediate recruitment of telomerase to the telomere.³³ Both mutant versions of hTERT (Leu55Gln and Thr1110Met) had impaired activity, as compared with the wild-type enzyme (Fig. 3C and 3D). Since heterozygous mutations sometimes interfere with the function of the wild-type allele, we assayed the telomerase activity of a mixture of wild-type and mutant versions of the enzyme and observed no dominant negative effect (data not shown).

We also examined the effect of the hTR 98 G→A substitution (observed in the proband of Family F) on telomerase activity. This mutation is predicted to impair base pairing in a helix in the essential pseudoknot domain of hTR.³⁴ Moreover, since 98G is conserved in telomerase RNA in all vertebrates, a mutation at this site is expected to alter activity.³⁴ When telomerase was reconstituted with the mutant hTR 98A allele, activity was severely impaired (Fig. 3C and 3D).

We next examined the potential consequences of the three mutations in hTERT. The deletion of nucleotide C at codon 112 in the proband of Family C leads to a frameshift mutation and is predicted to result in a nonfunctional, truncated protein. Both splice-junction mutations in Family B and Family D occur at consensus sequences that are conserved in 99.9% of all eukaryotic genes and are therefore predicted to alter splicing. We examined the cDNA of primary cells from a subject in Family D who carried the IVS9-2 A→C mutation and observed skipping of exon 10 but retention of the reading frame (Fig. 3E). According to these findings, obtained by RT-PCR, synthesis of a protein of nearly full length is predicted. However, this mutant TERT is predicted to lack an essential motif (the C motif) in the reverse-transcriptase domain and thus to result in a functionally null protein (Fig. 3A).⁸

CLINICAL REVIEW

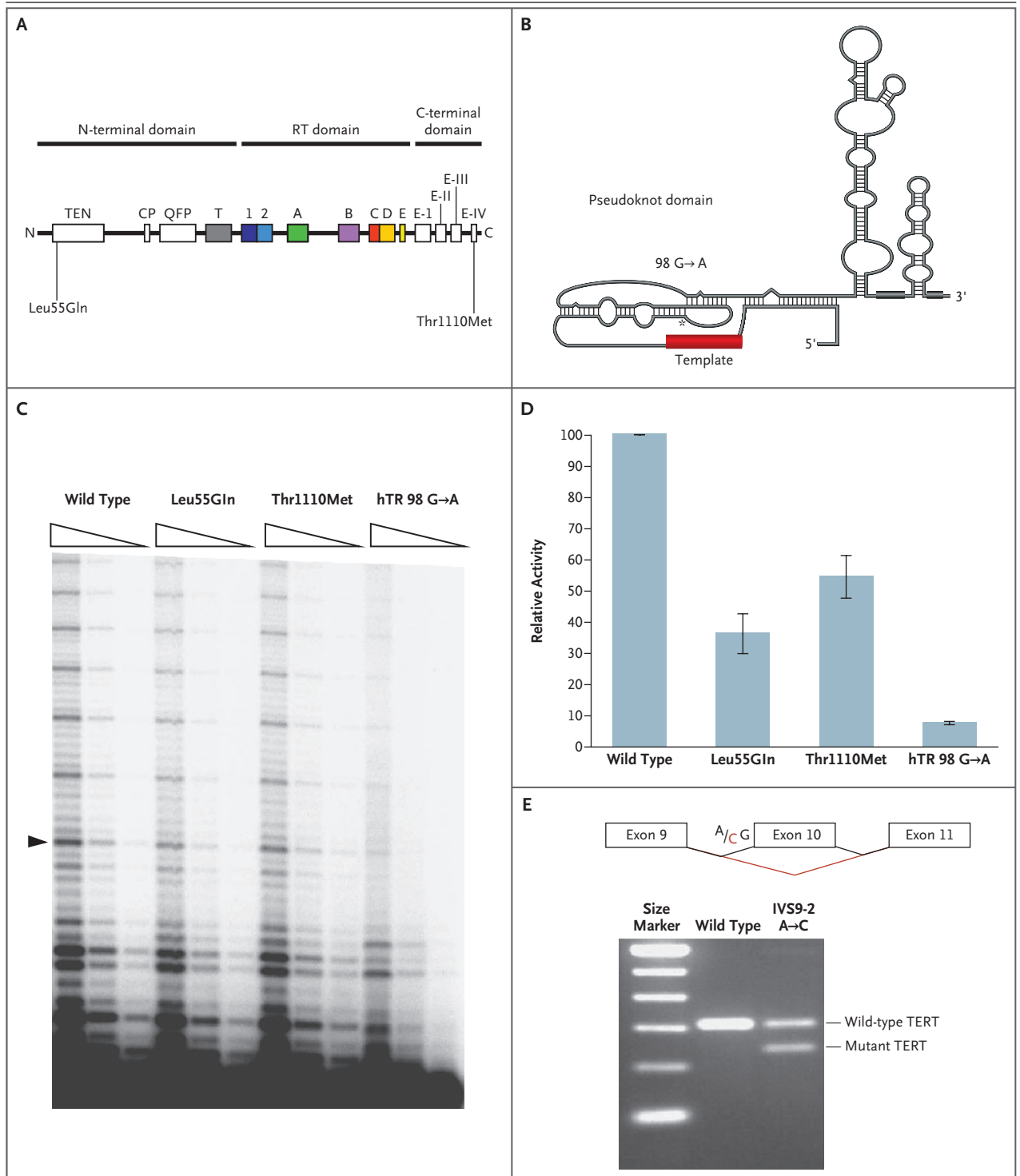
We reexamined the probands for the most common features of dyskeratosis congenita. None of the probands had cytopenias (Table 1), and none had any of the classic features of dyskeratosis congenita at the time of diagnosis. To discern whether these six families had hidden cases of dyskeratosis congenita, we queried family members and

Figure 3 (facing page). Biochemical Consequences of Telomerase Mutations in Proband.

Panel A shows conserved domains of hTERT with missense mutations, as indicated. Colors indicate conserved domains in hTERT shared with other reverse transcriptases. The Leu55Gln mutation lies in the telomerase essential N-terminal (TEN) domain, and Thr1110Met is in one of four conserved C-terminal domains. Panel B shows the secondary structure of hTR, with the site of the mutation indicated by an asterisk. The 98 G→A substitution lies in a critical helix of the pseudoknot domain, which contains the telomere template and is responsible for binding to TERT. Panel C shows the telomerase activity of mutant hTERT and hTR alleles, as measured by the direct assay and the intensity and pattern of the repetitive ladder. Panel D shows the quantitation of telomerase activity at the second major band, as indicated by the arrowhead in Panel C. Mean activity was calculated on the basis of three to five experiments; the I bars represent standard errors. Panel E shows the results of an RT-PCR assay across exons 9 through 11 from a subject with an hTERT 9-2 A→C mutation, indicating that the heterozygous mutation at this consensus splice junction leads to the skipping of exon 10. As a result, the mutant TERT lacks the essential motif C of the reverse-transcriptase domain.

medical records for evidence of aplastic anemia. We identified no cases of aplastic anemia in five of the six families. In Family F, we identified three subjects with aplastic anemia and a fourth subject with probable aplastic anemia (Fig. 1). In this family, subjects with a hematopoietic defect died at a younger age (25, 26, 31, and 81 years, with a mean of 41 years) than did those with idiopathic pulmonary fibrosis (76, 70, 63, 57, 60, and 66 years, with a mean of 65 years). We also explored the possibility that asymptomatic mutation carriers with short telomeres had cytopenias that reflected early changes of aplastic anemia. We examined complete blood counts in members of five of the families — Family A, Family B, Family C, Family D, and Family E — and found no abnormalities.

To assess whether the pulmonary fibrosis in the probands could be differentiated from other cases of idiopathic pulmonary fibrosis, we reviewed the clinical data. The presentation, age at onset, and findings on computed tomography were indistinguishable from those of other cases of the disease (Table 1 and Fig. 4). None of these subjects had a response to trials of immunosuppressive therapy. In all cases, the proband had



undergone lung biopsy, and five of the six probands had the common lesion of usual interstitial pneumonia. A biopsy specimen obtained from the sixth proband showed idiopathic interstitial pneumonia, not classifiable. Different idiopathic inter-

stitial pneumonia pathological lesions have been described in the same patient, as well as in members of the same family with the disease, underscoring the need for precise molecular characterization.^{4,35}

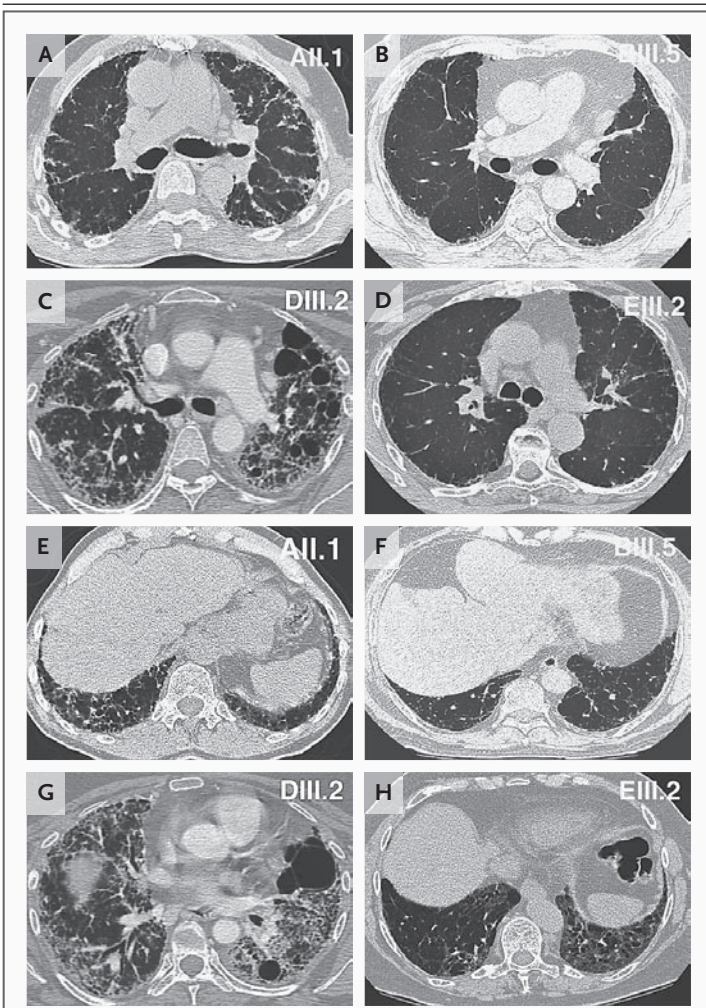


Figure 4. High-Resolution Computed Tomographic Images of the Midlung (Panel A through Panel D) and Bases (Panel E through Panel H) in Probands in Four Families.

Subject numbers are shown in the upper right-hand corners of the panels. In all four probands, subpleural honeycombing and increased reticular densities are visible in the views at the bases. These changes extend up to the midlung and apices in some subjects with more advanced stages of disease (e.g., Subject DIII.2).

DISCUSSION

We have shown that mutant telomerase is associated with familial idiopathic pulmonary fibrosis, which suggests that the spectrum of disease caused by telomere shortening is more extensive than previously appreciated and that a subgroup of families with pulmonary fibrosis falls on that spectrum.

Short dysfunctional telomeres activate a DNA

damage response that leads to cell death or cell-cycle arrest. This response is manifested clinically as organ failure in tissues of high turnover (bone marrow, skin, and gastrointestinal tract) in patients with, and in an animal model of, dyskeratosis congenita.^{14,24} The presence of pulmonary fibrosis in dyskeratosis congenita, along with the presence of telomerase mutations in some families with idiopathic pulmonary fibrosis, suggests that bronchoalveolar epithelium is also constantly replaced and relies on local progenitor reserves that are limited by short telomeres.

On the basis of these findings, we propose that the fibrotic lesion in patients with short telomeres is provoked by a loss of alveolar cells rather than by a primary fibrogenic process, such as one that would seem to occur in autoimmune disease associated with lung fibrosis. This view is supported by the fact that misfolded surfactant protein C (present in affected subjects carrying a mutation in the corresponding gene) appears to be toxic to alveolar cells.⁴ Therefore, it is possible that in some types of fibrosis, damage of epithelial cells leads to a remodeling response that appears clinically as usual interstitial pneumonia. Taken together, these considerations may explain the lack of success in reversing idiopathic fibrosis with agents that modulate immune or inflammatory signals and support the idea that at least in some cases, strategies aimed at preventing the loss of alveolar cells, or local responses to such cell loss, may have a greater clinical impact.

Although mutations in the essential components of telomerase do not seem to account for a majority of cases of familial pulmonary fibrosis, telomere shortening as a process may still contribute to the pathogenesis. There is evidence that short telomeres, rather than telomerase mutations, correlate with disease in dyskeratosis congenita. In an animal model of dyskeratosis congenita, wild-type mice who inherit short telomeres appear to have an occult genetic disease and display phenotypes similar to those in mice that are heterozygous for mutant telomerase RNA.¹⁴ Acquired states that increase tissue turnover are also associated with short telomeres. One study showed that both current and former smokers had shorter telomeres than did age-matched nonsmokers.³⁶ In addition, there is some evidence that telomeres of the alveolar epithelium in smokers are shorter than those of the alveolar

epithelium in nonsmokers.³⁷ It is therefore possible that somatic telomere shortening, caused by conditions that increase cell turnover (e.g., smoking), could contribute to fibrosis. In a study evaluating disease onset in relatives of familial probands with idiopathic pulmonary fibrosis, cigarette smoking and older age were the strongest predictors.³⁵ Because telomere shortening occurs with aging and can be acquired, it may contribute to the disease pathogenesis even in persons with wild-type telomerase.

Our study will have clinical implications, assuming that our findings are replicated by other investigators. As suggested by the experience in aplastic anemia,²³ patients who carry either *hTERT* or *hTR* mutations are unlikely to have a response to immunosuppression and may be good candidates for investigational clinical trials. The presence of a diagnostic genetic test gives patients at risk and their clinicians a chance to consider early screening and evaluation tailored to identification of complications of dyskeratosis congenita. Patients with dyskeratosis congenita, especially those with severe forms, have a predisposition to cancers of the skin, hematopoietic system, and oral mucosa.

Finally, telomere length may serve as a surrogate marker for the identification of patients at greatest risk for carrying mutant telomerase genes.

In our series of 15 subjects, longer telomeres appeared to predict the absence of a telomerase mutation, although this finding requires verification in larger studies. Since the consequences of carrying mutant telomerase genes can appear in adulthood as either idiopathic pulmonary fibrosis or aplastic anemia without dyskeratosis, the consideration of such cases as part of a syndrome of telomere shortening may heighten the index of suspicion and facilitate diagnosis.

Supported by a grant (NCI K08 118416) from the National Institutes of Health (NIH) (to Dr. Armanios), the Richard C. Ross Johns Hopkins School of Medicine Clinician Scientist Award (to Dr. Armanios), the Maryland Cigarette Restitution Fund (to Johns Hopkins University), a grant from the Johns Hopkins Institute for Cellular Engineering Pilot Program (to Dr. Greider), a grant (HL K08 85406) from the NIH and the Francis Family Foundation (to Dr. Lawson), a grant (AI29524) from the NIH and grants (MOP38075 and GMH79042) from the Canadian Institute of Health Research (to Dr. Lansdorp), a Vanderbilt Discovery Grant and the Rudy W. Jacobson endowment (to Dr. Loyd), and a grant (M01 RR-00095) from the National Center for Research Resources of the NIH to support the Vanderbilt Clinical Research Center.

Dr. Lansdorp reports being a founding shareholder in Repeat Diagnostics, a company that specializes in length measurement of leukocyte telomeres with the use of flow FISH. No other potential conflict of interest relevant to this article was reported.

We thank the subjects and their families who participated in this study and their clinicians, especially Drs. Adaani Frost and Keith E. Kelly and nurses Wendi Mason and Rhonda Greer; the Johns Hopkins Fragment Analysis Laboratory and Laura Kasch-Semenza for their help with DNA sequencing; Melissa Prince for technical assistance; and Dr. David Valle for his valuable advice.

REFERENCES

1. Lawson WE, Loyd JE. The genetic approach in pulmonary fibrosis: can it provide clues to this complex disease? *Proc Am Thorac Soc* 2006;3:345-9.
2. Loyd JE. Pulmonary fibrosis in families. *Am J Respir Cell Mol Biol* 2003;29:Suppl:S47-S50.
3. Marshall RP, Puddicombe A, Cookson WO, Laurent GJ. Adult familial cryptogenic fibrosing alveolitis in the United Kingdom. *Thorax* 2000;55:143-6.
4. Thomas AQ, Lane K, Phillips J III, et al. Heterozygosity for a surfactant protein C gene mutation associated with usual interstitial pneumonitis and cellular non-specific interstitial pneumonitis in one kindred. *Am J Respir Crit Care Med* 2002;165:1322-8.
5. Greider CW, Blackburn EH. Identification of a specific telomere terminal transferase activity in *Tetrahymena* extracts. *Cell* 1985;43:405-13.
6. *Idem*. A telomeric sequence in the RNA of *Tetrahymena* telomerase required for telomere repeat synthesis. *Nature* 1989;337:331-7.
7. Nakamura TM, Morin GB, Chapman KB, et al. Telomerase catalytic subunit homologs from fission yeast and human. *Science* 1997;277:955-9.
8. Lingner J, Hughes TR, Shevchenko A, Mann M, Lundblad V, Cech TR. Reverse transcriptase motifs in the catalytic subunit of telomerase. *Science* 1997;276:561-7.
9. Harley CB, Futcher AB, Greider CW. Telomeres shorten during ageing of human fibroblasts. *Nature* 1990;345:458-60.
10. Vaziri H, Dragowska W, Allsopp RC, Thomas TE, Harley CB, Lansdorp PM. Evidence for a mitotic clock in human hematopoietic stem cells: loss of telomeric DNA with age. *Proc Natl Acad Sci U S A* 1994;91:9857-60.
11. Lee HW, Blasco MA, Gottlieb GJ, Horner JW II, Greider CW, DePinho RA. Essential role of mouse telomerase in highly proliferative organs. *Nature* 1998;392:569-74.
12. d'Adda di Fagagna F, Reaper PM, Clay-Farrace L, et al. A DNA damage checkpoint response in telomere-initiated senescence. *Nature* 2003;426:194-8.
13. Hemann MT, Strong MA, Hao LY, Greider CW. The shortest telomere, not average telomere length, is critical for cell viability and chromosome stability. *Cell* 2001;107:67-77.
14. Hao LY, Armanios M, Strong MA, et al. Short telomeres, in the presence of telomerase, limit tissue renewal capacity. *Cell* 2005;123:1121-31.
15. Rudolph KL, Chang S, Lee HW, et al. Longevity, stress response, and cancer in aging telomerase-deficient mice. *Cell* 1999;96:701-12.
16. Dokal I, Vulliamy T. Dyskeratosis congenita: its link to telomerase and aplastic anaemia. *Blood Rev* 2003;17:217-25.
17. Dokal I. Dyskeratosis congenita in all its forms. *Br J Haematol* 2000;110:768-79.
18. Knight S, Vulliamy T, Copplestone A, Gluckman E, Mason P, Dokal I. Dyskeratosis Congenita (DC) Registry: identification of new features of DC. *Br J Haematol* 1998;103:990-6.
19. Heiss NS, Knight SW, Vulliamy TJ, et al. X-linked dyskeratosis congenita is caused by mutations in a highly conserved gene with putative nucleolar functions. *Nat Genet* 1998;19:32-8.
20. Fogarty PF, Yamaguchi H, Wiestner A,

- et al. Late presentation of dyskeratosis congenita as apparently acquired aplastic anaemia due to mutations in telomerase RNA. *Lancet* 2003;362:1628-30.
21. Vulliamy T, Marrone A, Goldman F, et al. The RNA component of telomerase is mutated in autosomal dominant dyskeratosis congenita. *Nature* 2001;413:432-5.
22. Yamaguchi H, Baerlocher GM, Lansdorp PM, et al. Mutations of the human telomerase RNA gene (TERC) in aplastic anemia and myelodysplastic syndrome. *Blood* 2003;102:916-8.
23. Yamaguchi H, Calado RT, Ly H, et al. Mutations in TERT, the gene for telomerase reverse transcriptase, in aplastic anemia. *N Engl J Med* 2005;352:1413-24.
24. Armanios M, Chen JL, Chang YP, et al. Haploinsufficiency of telomerase reverse transcriptase leads to anticipation in autosomal dominant dyskeratosis congenita. *Proc Natl Acad Sci U S A* 2005;102:15960-4.
25. Vulliamy T, Marrone A, Szydlo R, Walne A, Mason PJ, Dokal I. Disease anticipation is associated with progressive telomere shortening in families with dyskeratosis congenita due to mutations in TERC. *Nat Genet* 2004;36:447-9.
26. Blasco MA, Lee HW, Hande MP, et al. Telomere shortening and tumor formation by mouse cells lacking telomerase RNA. *Cell* 1997;91:25-34.
27. American Thoracic Society/European Respiratory Society International Multidisciplinary Consensus Classification of the Idiopathic Interstitial Pneumonias: this joint statement of the American Thoracic Society (ATS), and the European Respiratory Society (ERS) was adopted by the ATS board of directors, June 2001 and by the ERS Executive Committee, June 2001. *Am J Respir Crit Care Med* 2002;165:277-304. [Erratum, *Am J Respir Crit Care Med* 2002;166:426.]
28. Baerlocher GM, Vulto V, de Jong G, Lansdorp PM. Flow cytometry and FISH to measure the average length of telomeres (flow FISH). *Nat Protoc* (in press).
29. Chen JL, Greider CW. Template boundary definition in mammalian telomerase. *Genes Dev* 2003;17:2747-52.
30. Drosopoulos WC, Dizenzo R, Prasad VR. Human telomerase RNA template sequence is a determinant of telomere repeat extension rate. *J Biol Chem* 2005;280:32801-10.
31. National Institute of Environmental Health Sciences. TERT: telomerase reverse transcriptase. (Accessed March 5, 2007, at <http://egp.gs.washington.edu/data/tert/>)
32. Jacobs SA, Podell ER, Cech TR. Crystal structure of the essential N-terminal domain of telomerase reverse transcriptase. *Nat Struct Mol Biol* 2006;13:218-25.
33. Autexier C, Lue NF. The structure and function of telomerase reverse transcriptase. *Annu Rev Biochem* 2006;75:493-517.
34. Chen JL, Blasco MA, Greider CW. Secondary structure of vertebrate telomerase RNA. *Cell* 2000;100:503-14.
35. Steele MP, Speer MC, Loyd JE, et al. Clinical and pathologic features of familial interstitial pneumonia. *Am J Respir Crit Care Med* 2005;172:1146-52.
36. Valdes AM, Andrew T, Gardner JP, et al. Obesity, cigarette smoking, and telomere length in women. *Lancet* 2005;366:662-4.
37. Tsuji T, Aoshiba K, Nagai A. Alveolar cell senescence in patients with pulmonary emphysema. *Am J Respir Crit Care Med* 2006;174:886-93.

Copyright © 2007 Massachusetts Medical Society.

FULL TEXT OF ALL JOURNAL ARTICLES ON THE WORLD WIDE WEB

Access to the complete text of the *Journal* on the Internet is free to all subscribers. To use this Web site, subscribers should go to the *Journal's* home page (www.nejm.org) and register by entering their names and subscriber numbers as they appear on their mailing labels. After this one-time registration, subscribers can use their passwords to log on for electronic access to the entire *Journal* from any computer that is connected to the Internet. Features include a library of all issues since January 1993 and abstracts since January 1975, a full-text search capacity, and a personal archive for saving articles and search results of interest. All articles can be printed in a format that is virtually identical to that of the typeset pages. Beginning 6 months after publication, the full text of all Original Articles and Special Articles is available free to nonsubscribers who have completed a brief registration.